

Registration and Analysis in Retinal Images for Diagnosis and Monitoring

ZohaSaeed Wadwan¹, Dr.S.R.Ganorkar²PG Student, Department of ETC, Sinhgad College of Engineering, Vadgaon (BK), Pune, Savitribai Phule Pune
University, Pune India.Professor, Department of ETC, Sinhgad College of Engineering, Vadgaon (BK), Pune, Savitribai Phule Pune
University, Pune India.

ABSTRACT: Fundus imaging is a champion amongst the most unending utilized structures for screening, finding of eye burdens and variations from the norm identified with vessels. Optic plate, veins are the essential perspectives of the fundus retinal pictures. On the off chance that the illness is perceived before then the visual fiasco can be avoided. Along these lines altered examination of fundus pictures is remarkably basic and can be utilized to strengthen brief determination in ophthalmology as the shape and size of vein and optic circle is a key pointer of different eye diseases, for example, diabetic retinopathy and glaucoma. The reason of different changed assessments or finding is the division of retina amazingly the recognizing confirmation of optic plate and division of the retinal vessels. The soundness is related and isolated on open Database Drive. In this work, a procedure has been shown to area the optic plate, Blood vessels and exudates. Determination of diabetic retinopathy at early stage should be possible through disclosure of Blood Vessels of retina. Vein division is a profitable contraption in the treatment of diabetic retinopathy.

KEYWORDS: blood vessel, exudates, image processing, mask, optic disc

I.INTRODUCTION

Diabetes impacts vision by making waterfall, glaucoma or more all diabetic retinopathy. Diabetic Retinopathy generally happens when little Blood Vessels gets hurt in the retina in light of high glucose level. This condition tends to happen in patients who have diabetes for 5 or more years [1]. Disseminates in retina happening from eye ailments are broke down by particular pictures and are come to fruition in light of optic imaging known as fundus [2]. Examination of shading fundus pictures may analyze and screen the advancement of general sicknesses like diabetes, cardiovascular maladies, and stroke and eye infections [2]. As we realize that optic disc, fovea and Blood Vessels are the points of interest of retinal fundus pictures. Optic disc is the brilliant district in the retinal picture and the development of Blood Vessel happens from its inside. The identification of optic disc in Retinal fundus pictures are thought to be the one of the primary stride [3]. Any adjustment fit as a fiddle, size, and shade of OD is an essential marker of different pathologies identified with eye, for example, glaucoma, consequently OD zone are utilized to gauge strange components that happens because of various retinopathies and it can be diabetic retinopathy and glaucoma [3] [4]. Exudates are one of the injuries of diabetic retinopathy and they have comparable balance and shading with that of optic disc. Distinguishing proof and evacuation of the OD helps in enhancing the grouping of exudates locales. Blood Vessel is a standout amongst the most imperative elements as it contains conduits and Blood Vessels and it helps in identifying retinal Blood Vessel impediment, hypertension and early finding and glaucoma [5]. Henceforth by checking the obtained changes in an early stage can help the ophthalmologist to analyze the illness. Other than that if the extraction of optic disc and Blood Vessels is done physically it would be troublesome and take more opportunity to get to [5]. Accordingly in today's opportunity mechanized location of typical and irregular components in retinal pictures pulling in a ton of analysts in restorative picture as it decrease the seriousness of the malady by sparing their time. Consequently if there is a requirement for solid programmed retinal vessel extraction then it must tail some conditions. They are (i) The Blood Vessel can have diverse width extending from expansive pixels to little pixels and in various bearings; (ii) Several components can show up in retinal picture comprising of optic disc, fovea and exudates, and they

International Journal of Innovative Research in Science, Engineering and Technology

(An ISO 3297: 2007 Certified Organization)

Vol. 5, Issue 6, June 2016

crush programmed Blood Vessel division; and (iii) The vessel differentiation is typically feeble and the little vessels are encompassed by clamors like Gaussian, salt and pepper [5]. Retinal Blood Vessels and optic disc division is the primary stage in programmed enlistment of two retinal fundus pictures identified with a patient and aides in checking of advancement of his infection at various times [5] [6].

II. RELATED WORK

A. W. Reza *et al.* [1] proposed a strategy for identification of Blood Vessel in retinal fundus pictures in light of RGB parts and quadtree deterioration. The proposed technique makes utilization of middle sifting, quadtree deterioration, and morphological recreation on retinal pictures. The use of pre-handling helps in enhancing the differentiation of the picture by making it more valuable for resulting examination. Quadtree deterioration gives data about the diverse sorts of pieces and intensities of pixels inside the squares. The proposed calculation utilized three shading segments and tried on different accessible databases.

K. Jeyasriet *al.* [2] proposed another calculation for the discovery of Blood Vessels. Firstly improvement of the picture is done with the assistance of curvelet change. Morphology handling with multistructural components is utilized to concentrate Blood Vessels from retinal pictures. A straightforward thresholding with associated segments investigation shows the remaining edges demonstrate the remaining edges having a place with vessels.

A. W. Reza *et al.* [3] proposed a calculation for the extraction of OD, exudates and cotton fleece spots from fundus pictures in light of marker controlled watershed division is utilized. Normal sifting and difference alteration are utilized as pre-processing ventures as a part of the proposed calculation. The execution is assessed on the test pictures of Stare and Drive.

Ana Maria Mendonca *et al.* [4] exhibited a calculation for the division of vessel tree in retinal pictures. In the initial step they removed out the vessel centrelines, which are utilized for the vessel filling stage. In the last division is finished with the assistance of iterative district developing strategy.

Ahmed HamzaAsadet *al.* [5] utilized two characterization issues. They proposed the possibility of subterranean insect state framework for programmed division of retinal Blood Vessels. The principal change is finished with the assistance of discriminant elements. The second should be possible with the assistance of use of new heuristic model in view of likelihood hypothesis.

G. B. Kandeet *al.* [7] proposed two distinctive methodologies for programmed identification and division of exudates and optic disc. The focal point of the optic disc is evaluated with the assistance of finding a point which has most extreme nearby difference. The limit of the optic disc is situated with the assistance of geometric dynamic shape. For exudates discovery the upgraded sections are separated with the assistance of spatially weighted fluffy c-implies grouping calculation.

D. Welferet *al.* [8] proposed another technique taking into account scientific morphology for identification of exudates in retinal fundus pictures. The assessment of the proposed strategy was done on openly accessible database DIARETDB1.

III. NORMAL FEATURES OF RETINAL FUNDUS IMAGES

Each sound retina has some ordinary elements. These ordinary elements are optic disc, Blood Vessels and fovea. Aside from these, an unfortunate retina may have some anomalous elements like hemorrhages; miniaturized scale aneurysms and exudates. A portion of the ordinary elements are examined underneath –

- (i) Optic disc
- (ii) Blood Vessels
- (iii) Fovea

International Journal of Innovative Research in Science, Engineering and Technology

(An ISO 3297: 2007 Certified Organization)

Vol. 5, Issue 6, June 2016

1. Optic disc

Optic disc is the section point for the significant Blood Vessels that supply the retina. The optic disc is the splendid gap in the back of the eye [7]. The area of the optic disc is an essential perspective in retinal picture investigation and discovery as it is a huge historic point highlight in the retina.

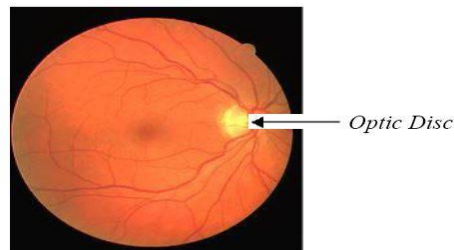


Figure 1: Optic Disc is the bright area on the right where blood vessels converge

2. Blood Vessels

The retina at the back of our eye requires a consistent blood supply. The blood supply ought to be productive so that the cells of the retina get every one of the supplements they have to keep working. There are two principle sorts of Blood Vessels – supply routes and Blood Vessels. Corridors convey crisp blood from the heart and lungs to your eye and Blood Vessels take away the blood that has been utilized by the eye and return it to the lungs and heart

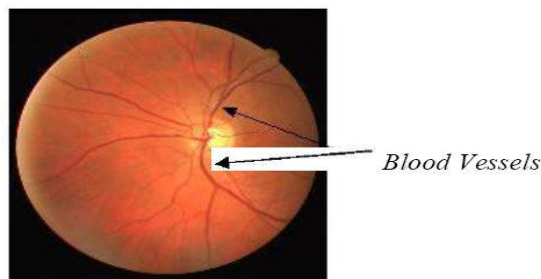


Figure 2: Blood vessels emerging from the center of the disc

3. Fovea

The fovea depicts the center of the retina and it is located in the center of macula which is the region of highest visual activity [8].

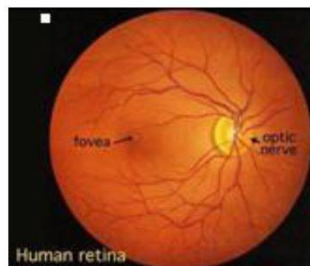


Figure 3: Fovea

International Journal of Innovative Research in Science, Engineering and Technology

(An ISO 3297: 2007 Certified Organization)

Vol. 5, Issue 6, June 2016

IV. OBJECTIVES

Primary objectives of this thesis are:

1. To study the points of interest and diverse injuries adding to the term Diabetic Retinopathy.
2. To study the technique proposed for optic disc expulsion.
3. To study the technique proposed for Blood Vessel division.
4. To study the strategy proposed for exudates location and classification of the image into healthy or affected.

V. METHODOLOGY USED

The technique is isolated into four stages: Pre-processing, Optic disc expulsion, Blood vessel division, and Detection of exudates. In the initial step of proposed technique points of interest are sectioned as it was depicted before they are optic disc and Blood Vessels. At that point in the following stride exudates are distinguished tackled an alternate picture. It demonstrates an outline of the proposed plan. To start with the retinal picture is taken from the database and changed over into dim scale picture. Fundamentally pre-processing steps incorporate difference improvement and enlargement and it is connected to the dark picture. Contrast Limited Adaptive Histogram Equalization (CLAHE) is connected as the first picture taken is obscured and the complexity is low. Thus to enhance the complexity of the picture is an extremely essential stride.

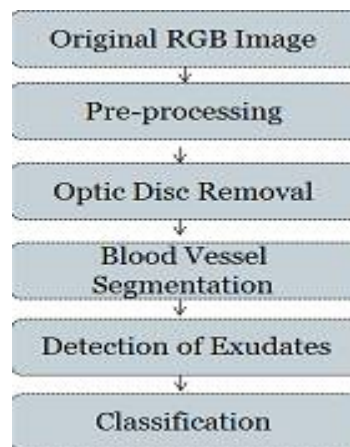


Figure 4: Flowchart of the proposed methodology

A. PRE-PROCESSING

Pre-processing of retinal picture is a vital stride and it helps in disentangling the accompanying strides, for example, Blood Vessel division, optic disc location and other strange structures.

STEPS FOR PREPROCESSING-

Step 1: Original Image

As a matter of first importance step is to secure a unique picture. They are initially RGB in nature and thus it is important to change over it into the dim scale picture.

Step 2: Greyscale picture

Subsequent to taking the first picture we are going to change over it into dim scale picture. As we realize that unique picture is RGB and just green and dim scale picture must be removed. Consequently greyscale picture is utilized for pre-processing. Greyscale picture is considered as the common premise for some division calculations.

International Journal of Innovative Research in Science, Engineering and Technology

(An ISO 3297: 2007 Certified Organization)

Vol. 5, Issue 6, June 2016

Step 3: Contrast Enhancement

Contrast upgrade is one of the principle parts of pre-handling. It subsequently enhances the difference of each area and along these lines helps in making the imperceptible elements of the picture more unmistakable. The principle motivation behind utilizing this strategy is that the CLAHE calculation parcels the pictures into various areas and afterward applies the histogram evening out to every district. Here the CLAHE calculation has connected on the dark picture. Prior straightforward histogram adjustment was likewise connected yet it demonstrated little change in the shading parity. That is the reason CLAHE is connected in this method rather than basic histogram evening out.

Significance of Pre-Processing

1. Enhances unique picture information
2. Helps in extricating morphological components
3. Morphological elements of various obsessive structures can be acquired
4. Gives vital data key to clinical analysis

B. OPTIC DISC REMOVAL

1. For evacuation of optic disc we are utilizing basic morphological technique.
2. Morphological opening is utilized for recognizable proof of the optic disc part.
3. The organizing component utilized for this object is "Ball" formed organizing component whose range is 8.
4. The opening picture is subtracted from the Enhanced picture result is evacuation of optic disc.
5. Opening and shutting are two vital administrators from scientific morphology. They are both gotten from the principal operations of disintegration and enlargement.
6. Like those administrators they are regularly connected to twofold pictures, despite the fact that there are likewise dim level forms.
7. The essential impact of an opening is to some degree like disintegration in that it tends to expel a portion of the closer view (brilliant) pixels from the edges of districts of frontal area pixels. Nonetheless it is less ruinous than disintegration when all is said in done.
8. As with other morphological administrators, the precise operation is dictated by an organizing component.
9. The impact of the administrator is to safeguard frontal area districts that have a comparative shape to this organizing component, or that can totally contain the organizing component, while dispensing with every other locale of closer view pixels.
10. Very just, an opening is characterized as disintegration took after by a opening utilizing the same organizing component for both operations. See the areas on disintegration and expansion for points of interest of the individual strides. The opening administrator in this way requires two inputs: a picture to be opened, and an organizing component.
11. Gray level opening comprises just of dark level disintegration took after by a dim level opening.
12. Opening is the double of shutting, i.e. opening the closer view pixels with a specific organizing component is identical to shutting the foundation pixels with the same component.

C. EXTRACTION OF BLOOD VESSELS USING KIRSCH'S TEMPLATES

The Kirsch administrator or Kirsch compass part is a non-straight edge identification that finds the most extreme edge quality in a couple pre-decided headings. The 'VESSEL EXTRACTION' board contains a popup menu with various limit values (inside a scope of 4.6 to 9.0) for Blood Vessel extraction. The Kirsch administrator can conform the related edge esteem consequently because of the picture attributes. The administrator takes a solitary bit veil and turns it in 45° augmentations through every one of the eight compass headings: North, North-West, West, South-West, South, South-East, East and North-East as demonstrated as follows:

International Journal of Innovative Research in Science, Engineering and Technology

(An ISO 3297: 2007 Certified Organization)

Vol. 5, Issue 6, June 2016

$$\begin{aligned}
 M1 &= \begin{pmatrix} 5 & 5 & 5 \\ -3 & 0 & -3 \\ -3 & -3 & -3 \end{pmatrix} & M2 &= \begin{pmatrix} 5 & 5 & -3 \\ 5 & 0 & -3 \\ -3 & -3 & -3 \end{pmatrix} & M3 &= \begin{pmatrix} 5 & -3 & -3 \\ 5 & 0 & -3 \\ 5 & -3 & -3 \end{pmatrix} & M4 &= \begin{pmatrix} -3 & -3 & -3 \\ 5 & 0 & -3 \\ 5 & 5 & -3 \end{pmatrix} \\
 M5 &= \begin{pmatrix} -3 & -3 & -3 \\ -3 & 0 & -3 \\ 5 & 5 & 5 \end{pmatrix} & M6 &= \begin{pmatrix} -3 & -3 & -3 \\ -3 & 0 & 5 \\ -3 & 5 & 5 \end{pmatrix} & M7 &= \begin{pmatrix} -3 & -3 & 5 \\ -3 & 0 & 5 \\ -3 & -3 & 5 \end{pmatrix} & M8 &= \begin{pmatrix} -3 & 5 & 5 \\ -3 & 0 & 5 \\ -3 & -3 & -3 \end{pmatrix}
 \end{aligned}$$

Figure 5: Kirsch Templates

The edge greatness of the Kirsch administrator is figured as the most extreme extent over all headings. But the furthest lines and sections, each pixel alongside its eight neighboring pixels in a given picture is convolved with the eight previously stated formats separately.

D. EXUDATE DETECTION

Early detection of DR is necessary for the prevention of visual loss. Hard exudates are one of the main signs of the DR. Due to their high occurrence; their detection would play an important role in the screening purpose, and helps in monitoring and for estimation of the disease. Hence automatic detection of exudates is a very crucial task because normally they have poor contrast, uneven illumination and colour variation in retinal fundus images. Exudates become difficult to identify as the stage of diabetic retinopathy changes. Most of the work has been done by the researchers for the detection of exudates. It has been watched that in the proposed strategy, exudates were plainly recognized from the optic disc. It demonstrates the upgraded exudates and is indicated plainly in the retinal fundus picture which is influenced by the diabetic retinopathy. Along these lines the morphological operation opening and thresholding is utilized to identify the nearness of exudates.

E. CLASSIFICATION USING SVM

It is important to classify the retinal images into healthy and affected images as to detect diabetic retinopathy. The classifier used is a SVM. SVMs are based on the SRM principle, in contrast to ERM principle in NNs, to minimize the error on the training data. SRMs minimizes a bound on the test error thus allowing SVMs to generalize better. The dataset is trained and then tested n identifies whether the retina is healthy or affected by DR.

VI. EXPERIEMENTAL SETUP

We realize that manual division and estimation of DR sores are very troublesome, tedious, and the client may commit errors moreover. The aftereffects of the division can differ contingent upon the picture quality and experience of client. Thus for this application certain standard parameters are utilized to assess the division exhibitions. Initial one is appeared in Eq. (1) and it decides the sensitivity of the division results. At the point when a pixel is delegated vessel in both the ground state and portioned state it is known as genuine positive. At the point when a pixel is delegated a non-vessel in the ground truth and fragmented picture it can be characterized as genuine negative. In false negative a pixel is delegated non-vessel in the sectioned picture yet as a vessel pixel in the ground truth picture. At the point when a pixel is set apart as vessel in the divided picture yet non vessel in the ground truth picture it is known as false positive. Some different parameters are utilized to introduce the outcomes in more reasonable structure. They are sure prescient quality (PPV), specificity and specificity.

Accuracy: The sensitivity is measured by the proportion of the aggregate number of accurately ordered pixels (entirety of genuine positive and genuine negative) to the quantity of pixels in the picture field of perspective.

$$Accuracy = \frac{(TN+TP)}{TN+TP+FN+FP} \dots (1)$$

Sensitivity is the extent of genuine positives arranged by the framework. Specificity is appeared by Eq. (3).

International Journal of Innovative Research in Science, Engineering and Technology

(An ISO 3297: 2007 Certified Organization)

Vol. 5, Issue 6, June 2016

$$\text{Sensitivity} = \text{TP}/(\text{TP}+\text{FN}) \quad \dots (2)$$

1. PRE-PROCESSING

In the accompanying segment consequences of the pre-processing are clarified beneath. The pre-processing is finished with the assistance of CLAHE calculation. The CLAHE calculation has been connected on the dark scale picture.

Step 1: In the step 1 it shows the result of the original image.

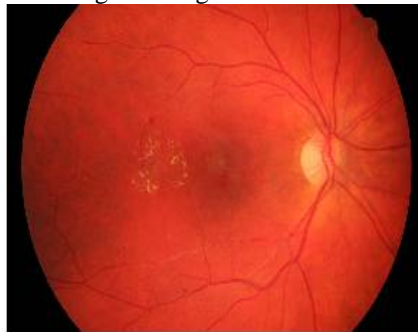

Figure 6: Original image

Step 2: Green channel inverted image-

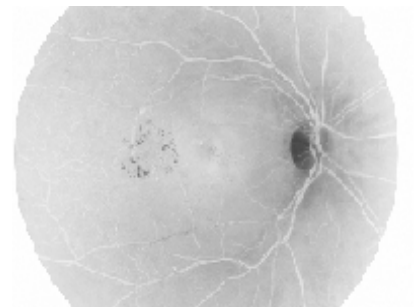


Figure 7: Inverted Green channel Image

Step 3: The result after applying CLAHE. The result shows that the contrast of the image has been improved and the optic disc and blood vessels are showing clearly. The methodology has been evaluated using publicly available database named Drive. It has been observed that the image after contrast enhancement is more illuminated and the details like blood vessels and optic disc are shown clearly. Also from the results it has been observed that the finer details of each and every region got enhanced. The area of the optic disc is more highlighted and can be used for optic disc detection. The method has been evaluated on Drive database and it contained 30 images divided into test and training set. Each set of test and training comprises 15 images. Contrast enhancement is applied on the entire test and training set and each image has shown improvement in contrast and the quality of the image has improved.

International Journal of Innovative Research in Science, Engineering and Technology

(An ISO 3297: 2007 Certified Organization)

Vol. 5, Issue 6, June 2016

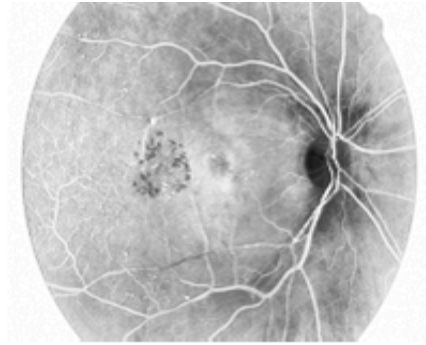

Figure 8: Contrast enhanced image

2. OPTIC DISC REMOVAL

The aftereffects of the optic disc expulsion are portrayed in the accompanying area as per the strides connected previously. As in the procedure a few techniques have been connected for optic disc evacuation. Optic disc is a vital point of interest in retinal fundus pictures and consequently it is key to evacuate for further finding. The outcomes are contrasted and the as of now proposed techniques depicted above and it has demonstrated better results in wording deciding the precise limits of brilliant questions particularly optic disc.

Step 1: The aftereffect of the pre-handled picture is here. The pre-processed picture is the same as portrayed in the above area.

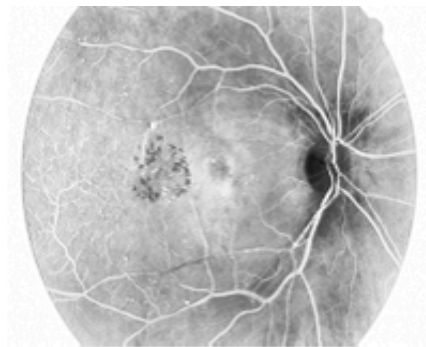


Figure 9: Contrast enhanced image

Step 2: The outcome in the wake of applying opening and thresholding is finished. In the wake of applying opening legitimate area of optic disc is appeared and in the wake of applying thresholding optic disc is expelled.

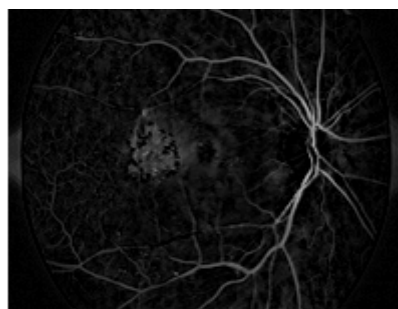


Figure 10: Optic disc removal

International Journal of Innovative Research in Science, Engineering and Technology

(An ISO 3297: 2007 Certified Organization)

Vol. 5, Issue 6, June 2016

3. BLOOD VESSEL SEGMENTATION

The course of edge is characterized by the related veil that creates the most extreme size. The general yield of edge identification through Kirsch's Templates is a picture containing Gray level pixels of worth 0 or 255. The quality 0 demonstrates a dark pixel and the worth 255 shows a white pixel. The edge data of the objective pixel is checked by deciding the shine levels of the neighboring pixels. On the off chance that no significant distinction in the brilliance level is found, the likelihood of the pixel being a part of an edge is precluded. Kirsch's Template can set and reset the limit qualities to acquire most reasonable edge of pictures. It functions admirably for pictures having a reasonable refinement between the closer view and foundation. Since the retinal Blood Vessels can be considered as the required frontal area data from the foundation fundus pictures, Kirsch's calculation is viably appropriate. It outlines a unique fundus picture with the separated Blood Vessels.

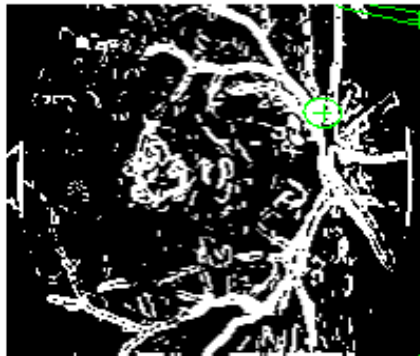


Figure 11: Blood Vessel Segmentation

4. EXUDATE DETECTION

Step 1: Exudates are hard yellowish deposits on the retina and is shown here.

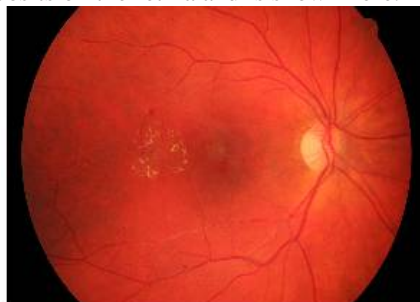

Figure 12: Original image containing exudates.

Step 2: It demonstrates the fragmented picture with exudates. They are isolated with the assistance of administrator. From the above results, it has been watched that in the proposed strategy, exudates were unmistakably recognized from the optic disc. It demonstrates the upgraded exudates and is indicated unmistakably in the retinal fundus picture which is influenced by the diabetic retinopathy. In this manner the morphological operation opening and thresholding is utilized to distinguish the nearness of exudates.

International Journal of Innovative Research in Science, Engineering and Technology

(An ISO 3297: 2007 Certified Organization)

Vol. 5, Issue 6, June 2016

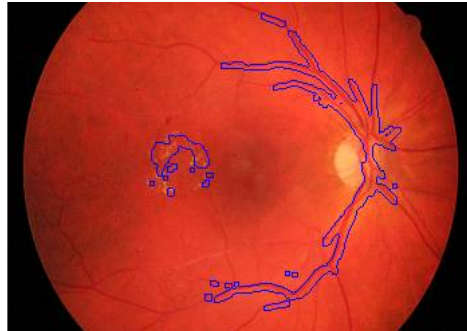

Figure 13: Exudates Detection

5. CLASSIFICATION

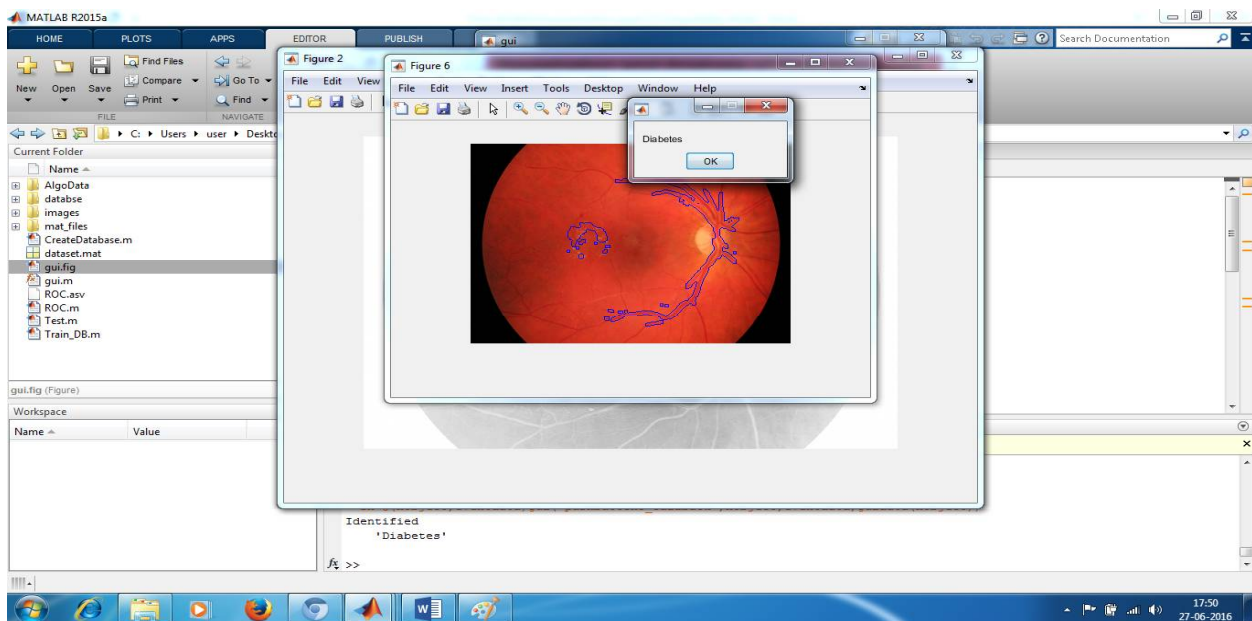


Figure 14: Detection of DR

International Journal of Innovative Research in Science, Engineering and Technology

(An ISO 3297: 2007 Certified Organization)

Vol. 5, Issue 6, June 2016

VII. GRAPH DISSCUSSION

1. ROC Curves SVM Classification

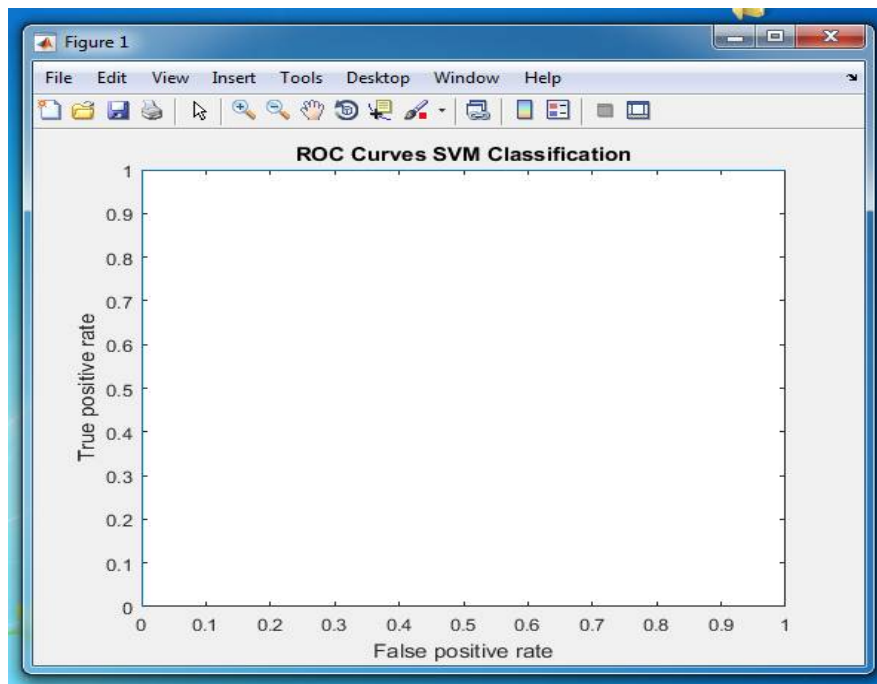


Figure 15: ROC curve

The ROC curve is showing 100% accuracy, that is, the 30 images from the database DRIVE are classified correctly into healthy and affected ones using SVM classifier.

VIII. CONCLUSION AND FUTURE WORK

A mechanized division technique for distinguishing veins, optic plate and exudates discovery in retinal pictures has been proposed. The system utilized a blend of various picture preparing methods and the use of Kirsch administrator for vein division. Optic Disk is evacuated utilizing morphological operations. Recognition of exudates is done utilizing morphological operations and DWT. The morphology has been tried and contrasted and two freely accessible databases Drive. Test results demonstrate that the outcomes accomplished with the proposed procedure are great and can be contrasted and the distributed results and practically equivalent to the execution of human eyewitnesses. Future work may incorporate recognition of components continuously frameworks.

REFERENCES

- [1] Reza, A.W. Eswaran, C., and Hati, S. Diabetic retinopathy: "A quadtree based Blood Vessel calculation utilizing RGB segments as a part of fundus pictures", J. Restorative Systems, vol 32, pp 147-155, 2008.
- [2] K. Jeyasri, P. Subathra, and K. Annaram, "Location of Blood Vessels for infection conclusion", International Journal of Advanced Research in Computer Science and Engineering", vol 13, pp 6 – 11, 2013.
- [3] A. W. Reza, C. Eswaran, K. Dimyati, "Analysis of Diabetic Retinopathy: Automatic Extraction of Optic disc and Exudates from Retinal Images utilizing Marker-controlled Watershed Transformation", J Medical System, vol 35, pp 1491 – 1501, 2011.
- [4] A. M. Mendonca, A. Campilho, "Division of retinal Blood Vessels by joining the location of centrelines and morphological development", IEEE Transactions on Medical Imaging, vol 25, pp 1200 – 1213, 2006.
- [5] Ahmed. H. Asad, A. T. Azar, M. M. M. Fouad, and A. E. Hassanien, "An enhanced subterranean insect province framework for retinal Blood Vessel division", Conference on Computer Science and Information Systems, pp 199 – 205, 2013.

International Journal of Innovative Research in Science, Engineering and Technology

(An ISO 3297: 2007 Certified Organization)

Vol. 5, Issue 6, June 2016

- [6] D. Marin, A. Aquino, M. E. Gegundez –Arias, J.M Bravo, "another directed technique for Blood Vessel division in retinal pictures by utilizing dark level and minute invariants based elements", IEEE Transactions on Medical Imaging, vol 30, pp 146 – 158, 2011.
- [7] G. B. Kande, P. V. Subbaih, and T. SatyaSavithri, "Division of exudates and optic plate in retinal pictures", sixth Indian Conference on Computer Vision, Graphics and Image Processing", pp 535 – 540, 2008.
- [8] D. Welfer, J. Scharcanski, D. RuschelMarinho, "A coarse to fine strategy for naturally recognizing exudates in shading eye fundus pictures", Computerized Medical Imaging and Graphics, vol 34, pp 228 - 235, 2010.
- [9] A.W. Reza, C. Eswaran, S. Hati, "Programmed following of optic disc and exudates from shading fundus pictures utilizing altered and variable limits", J. Restorative Systems, vol 33, pp 73-80, 2009.
- [10] AkaraSopharak, B. Uyyanonvarsa, S. Barman, T. H. Williamson, "Programmed Detection of diabetic retinopathy exudates from non-widened retinal pictures utilizing numerical morphology strategies", Computerized Medical Imaging and Graphics on ELSEVIER, vol 32, pp 720 – 727, 2008.
- [11] T. Walter, J. C Klein, P. Massin, and A. Erginay, "A commitment of picture handling to the analysis of diabetic retinopathy – Detection of Exudates in Color Fundus Images of the Human Retina", IEEE Transactions on Medical Imaging, vol 21, pp 1236 – 1241, 2002.
- [12] Mahendran Gandhi, and R. Dhanasekaran, "Conclusion of diabetic retinopathy utilizing morphological procedure and svm classifier", International Conference on correspondence and sign preparing", pp 873 - 877, 2013.
- [13] Eman M. Sahin, Taha E. Taha, W. Al-Nuiamy, S. El Rabaie, Osama F. Zahran, and Fathi E. Abd El-Samie, " Automated location of diabetic retinopathy in obscured computerized fundus pictures", IEEE Transactions on Medical Imaging , pp 20-25, 2012.
- [14] S. Ravishankar, A. Jain, and A. Mittal, "Robotized highlight extraction of early discovery of diabetic retinopathy in fundus pictures", International Conference in IEEE, pp 210-220, 2009.
- [15] M. G. FakhtarEadgahi, H. Pourreza, "Confinement of Hard Exudates in Retinal Fundus Image by Mathematical Morphological Methods.